

Improved Texture and Appearance of Human Facial Skin After Daily Topical Application of Barley Produced, Synthetic, Human-like Epidermal Growth Factor (EGF) Serum

Jonathan M. Schouest BS, Teresa K. Luu MD, and Ronald L. Moy MD
Moy-Fincher-Chipps Facial Plastics and Dermatology, Beverly Hills, CA

ABSTRACT

A three month, open-label, single center study was conducted to determine whether a uniquely derived serum containing barley bioengineered, human-like epidermal growth factor protein could improve visible signs of photodamage and aging in facial skin. Twenty-nine females, aged 39 to 75 years, with mild to severe, fine and coarse rhytids, photodamage, and pigmentation were enrolled. Subjects then applied the treatment serum per the prescribed protocol twice-daily for 3 months, in addition to the use of a basic sunscreen and facial cleanser. In-person clinical evaluations and subject self-assessment questionnaires were administered at each follow up visit. In addition, clinical photography was completed at baseline, and each subsequent visit. Clinical evaluations showed statistically significant improvement in the appearance of fine lines and rhytids, skin texture, pore size, and various dyschromatic conditions apparent within the first month of use, and continuing improvement trends for the duration of the study. The treatment serum was well tolerated with minimal treatment-related complications reported throughout. Efficacy of this novel serum and treatment protocol resulted in meaningful improvements in photodamage and visible signs of aging.

J Drugs Dermatol. 2012;11(5):613-620.

INTRODUCTION

Present in a wide variety of tissues and fluids, epidermal growth factor protein (EGF) acts on a subset of the tyrosine kinase receptor family.¹ Epidermal growth factor serves primarily in a mitogenic and mobilizing capacity on keratinocytes, fibroblasts, and smooth muscle cells. These findings have led to its successful use in improving healing times in corneal abrasions, radiation-induced mucositis, and diabetic ulcers.²⁻⁹ As humans naturally age, EGF receptors (EGFRs) and EGFR response appears to decrease.^{10,11} In addition to decreased EGFR activity, the epidermis thins and cosmetically significant signs of photodamage (wrinkles, dyschromia, and rough, loose skin) evolve over time as a result of decreased and abnormal dermal collagen and elastin and deregulated melanocyte activity.^{12,13} As topical EGF in other applications and studies has been well tolerated,¹⁴ we thus performed an open label clinical trial investigating the efficacy of a topically applied novel serum containing human-like EGF protein bioengineered from barley on the appearance and texture of skin in volunteers.

METHODS AND MATERIALS

This study employed a long-form subject-consent of the format commonly utilized by the Western Institutional Review Board, which conforms to the ethical guidelines of the 1975 Declaration of Helsinki. In addition, Standard Operating Procedures for Clinical Research in accordance with the appropriate Moy-Fincher-Chipps oversight committee, and Good Clinical Practice was observed. All subjects were regularly evaluated for changes in presentation of facial skin concurrent with a regimen of twice-daily topical application of EGF serum (BIOEFFECT EGF Serum, Figures 1 and 2).²⁵

Subjects were also given a proprietary botanical facial cleanser, Renewal Foaming Cleanser,²³ and SPF 30 sunscreen, DNA Defense SPF 30+.²⁴ These products constituted "The Regimen," which was followed for a compulsory 3-month period, with an optional 3-month extension totaling 6 months as tolerable by the subject. During the course of the study, Tretinoin, retinol and other Vitamin A derivatives, additional exfoliants, and corticosteroids were not used by any active subject.

FIGURE 1. EGF serum manufacture and origin, courtesy of Sif Cosmetics**DEFINITION OF INGREDIENTS SOURCE****Definition of the Plant Derived Ingredients *Transgenic Barley sh-Oligopeptide-1* and *Hordeum Vulgare* seed extract:**

- | | | |
|----|---|----------------------------------|
| 1. | Starting Material: | Aqueous extract of seeds |
| 2. | Plant Species: | <i>Hordeum Vulgare</i> (barley). |
| 3. | Part of plant used: | Seed |
| 4. | Country of Origin: | Iceland |
| 5. | Processing in brief: Aqueous extraction and purification by affinity chromatography. Analytical evidence provided in Western blot analysis confirming identity of the EGF cellular activator, the active ingredient of BIOEFFECT EGF Serum, with specific anti-EGF antibody. Neither animal ingredient nor animal-related ingredient is utilized in the process. | |

FIGURE 2. EGF serum chemical analysis and registry Identification**SUBSTANCE/CHEMICAL ANALYSIS**

CHEMICAL INFORMATION ON BARLEY PRODUCED EGF

1. **Active ingredient:** *synthetic human-like EGF cellular activator*
2. **Synonyms:** hEGF, *human Epidermal Growth Factor*
3. **Chemical Registry Numbers (for chemical synonyms):** EC# 263-468-7, CAS# 62229-50-9
4. **INCI name:** *Transgenic Barley sh-Oligopeptide-1*
5. **Molecular information:**

The *Transgenic Barley sh-Oligopeptide-1* is a human-like epidermal growth factor (sh-EGF) produced in barley seeds. The synthesized gene encodes for a human-like EGF but the synthesized gene is modified according to the genetic preferability of barley. After the transfer, this non-native synthetic segment of DNA produces the synthetic human-like (sh) Epidermal Growth Factor protein in the transgenic organism, the barley.

The inserted gene is shortened to give protein of 53 amino acids, which represents the mature soluble form of EGF. The synthetic human-like EGF protein migrates with an apparent molecular mass of 12 kDa in SDS-PAGE.

Clinical photography using standardized facial positioning was completed at baseline, and every subsequent 30 days, up to an optional maximum of 180 days. Twenty-one of twenty-nine enrolled subjects elected to terminate study involvement by the conclusion of the 3-month visit.

Photography was achieved with standard Canfield equipment. Subjects completed a 10 question survey at all follow-up visits rating individual perception of improvement in wrinkles, fine lines, brown spots (lentigines), red spots, age spots (seborrheic keratoses), and skin smoothness (perceived fine texture) on a five point scale. Several free form questions were also included to allow for individualized feedback on product use, etc. In addition, same-day clinical evaluation for improvement over baseline was completed at each follow up visit by the PI or designate on a nine-point scale, in increments of 0.5 (0=No im-

provement, 4.0=Extremely Marked Improvement), based on the categories of fine lines, wrinkles, dyschromias, and lack of skin smoothness. From data gathered, each category of measure was evaluated by student's paired t-tests for statistical significance, in addition to calculations for mean percentage improvement, simple mean, and standard deviation of applicable data sets.

Inclusion criteria: Self selected males and females of any racial/ethnic origin, of at least 30 years of age with clinically significant signs of photoaging as determined by dermatologist examination. Subject ability to follow treatment regimen and follow-up obligations.

Exclusion criteria: Recent subject history of colon, lung, breast, or skin cancer, history of allergic or hypersensitive reaction to any active ingredients in regimen. No at risk populations were studied.

FIGURE 3. Mean percentage change (improvement) in categorical cosmetic measurements compared with baseline. Note pore size reduction. For Month 1, n=23, for Month 2, n=19. $P < 0.0002$

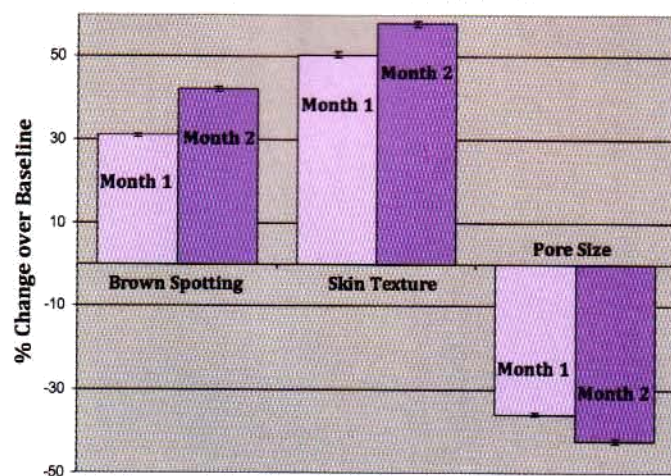
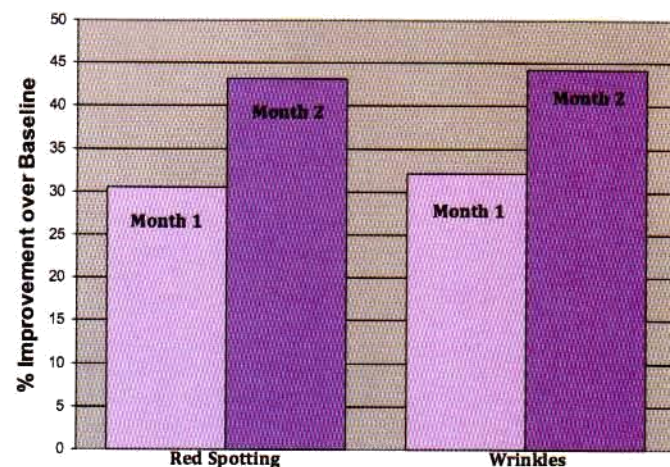


FIGURE 4. Mean percentage improvement in categorical cosmetic measurements compared with baseline. For Month 1, n=23, for Month 2, n=19. $P < 0.0002$



RESULTS

Twenty-nine subjects were enrolled in the study. Of this number, twenty-one completed the treatment course. One subject dropped out after observing minor dermatitic reactions of unknown origin within the treatment area. Although it was noted that the subject possessed a barley food allergy, studies of the utilized EGF serum have indicated negligible present trace elements and a low probability of cause. Another subject with a history of basal cell carcinoma was excluded after a new lesion was identified and required treatment, and six subjects were lost to follow-up due to time, distance, and non-response constraints. All subjects were female and between the ages of 39 and 75 years of age (mean 54.1 years), and 96% were Caucasian (1 Asian/Pacific Islander was enrolled). The majority—79% of subjects—were evaluated as a Fitzpatrick Skin Type II. Fitzpatrick Skin Type I comprised 17.5. Only 1 Subject was evaluated as a Fitzpatrick Type III. All subjects were immunocompetent and in general good health.

Statistical analyses of Clinical Evaluations and Subject Self Assessment Questionnaires were performed by student's paired t-test in each applicable case, and data were cross checked with standard deviation calculations. For Subject Self Assessment Questionnaires, mean values for each categorical skin measure were compared at Months 1 and 2 (and compiled separately for Month 3, due to format differences), while for Clinical Evaluation data, Month 1 and Month 3 data were compared in the same manner to achieve a "before and after" representation of improvement. Statistical significance was considered achieved at the $P < 0.05$ level.

For Subject Self Assessment Questionnaires, mean scores from positive responders in all skin measures (from months 1 and 2) were shown by students' paired t-test to be statistically sig-

nificant in all categories of skin condition, including, in Month 2 of evaluation, 42.1% improvement in Brown Spotting, 57.9% improvement in overall Skin Texture, and 42.4% reduction in apparent Pore Size ($P < 0.0002$) presented in Figure 3. Of note, the category of overall "skin texture" is most analogous to overall improvement in visible skin, which showed the most dramatic improvement by simple magnitude of any measure employed.

Figure 4 summarizes these mean percentage improvements with regard to Red Spotting (43.2%) and Wrinkles (44.2%) (also $P < 0.0002$) in the second month of regimen use compared to baseline. Figure 5 provides a case study example of significant dyschromia improvement in the malar cheek of a subject after 3 months of EGF use, while Figure 6 provides a similar example of glabellar rhytid (wrinkle) improvement and skin tightening over the course of the same 3-month study period. Both subjects were considered to be demographically typical with respect to the enrolled population.

Continuing improvement trends were also observed in the final Subject Self Assessment given during the course of the study, which assesses these same improvement categories but is of a slightly different format and is summarized later in Table 1.

Mean Clinical Evaluation scores during each follow-up visit in comparison to baseline also showed statistically significant improvement in all measures (fine lines, wrinkles, dyschromia, skin smoothness, or texture) when evaluated by students' paired t-test. Fine lines and wrinkles improved by a mean percentage of 11.9% and 15.2%, respectively, by the third month of treatment (the study endpoint), demonstrated in Figure 7. Meanwhile, dyschromia severity and count, as well as skin smoothness (texture) improved by 15.2% and 13.3%, respectively, over the same pe-

FIGURE 5. 44-year-old Caucasian female with malar cheek dyschromia improvement after 3 months of EGF use. Baseline (top) versus 90 days of use (bottom)

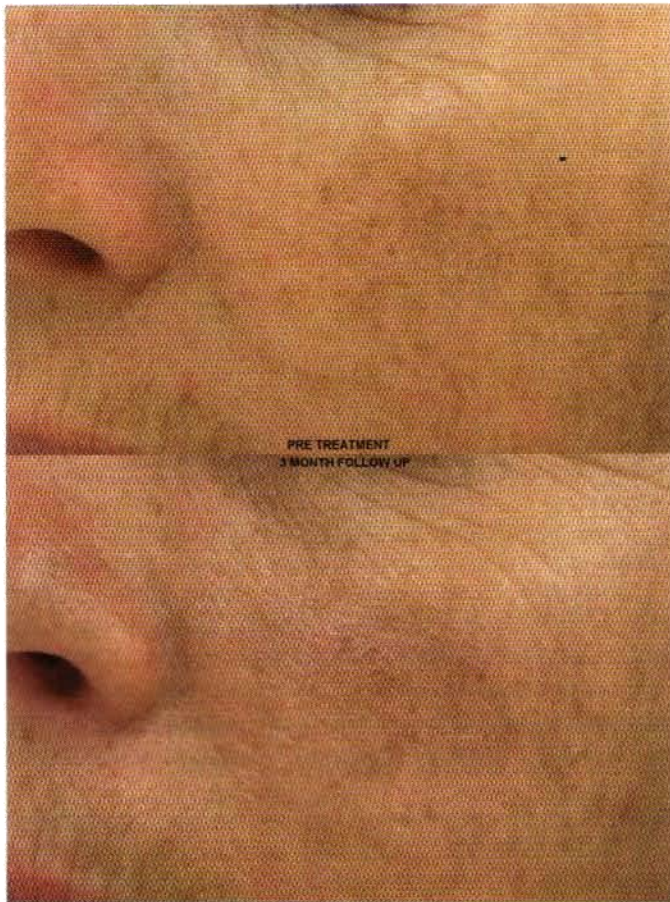
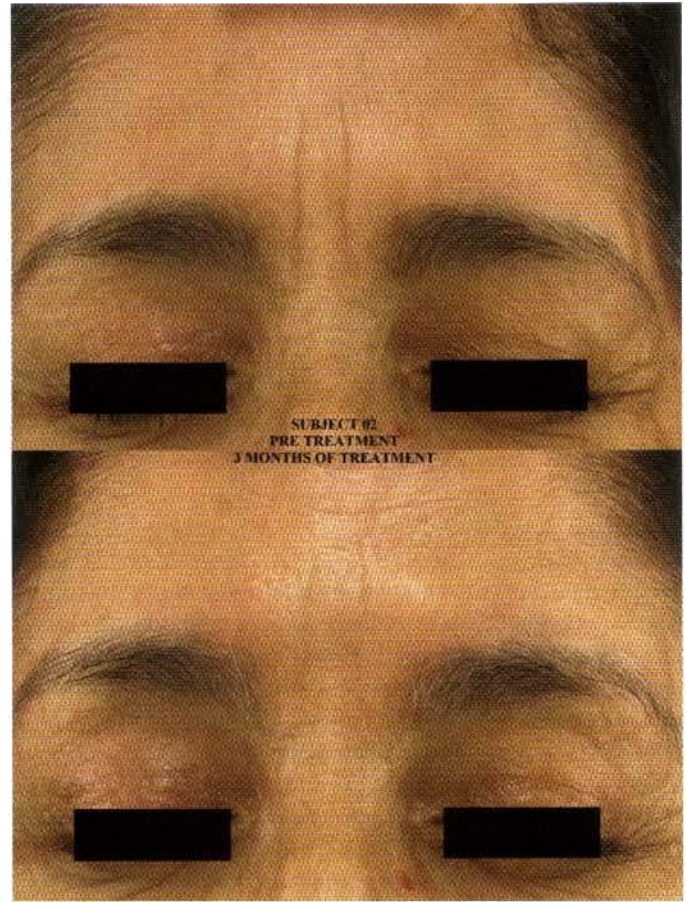


FIGURE 6. 63-year-old Asian/Pacific Islander female with glabellar rhytid improvement after 3 months of EGF use. Baseline (top) versus 90 days of use (bottom)



riod of time, as seen in Figure 8. *P* values for Month 1 and Month 3 data, evaluated for significance by student's paired *t*-test, was determined to be $P < 0.0022$ for all measures.

In the final Subject Self-Assessment (administered during the final clinical visit of the study), the percentage of subjects who selected great or moderate improvement in response to each categorical question is presented in Table 1. In all parameters, except "age spots" and "wrinkles," greater than 50% of subjects selected one of these two choices, with 80% of respondents selecting one of these choices in description of their improvement in skin smoothness (fine texture). If data is selected for any visible improvement, 100% of respondents expressed noticeable improvement in wrinkles, fine lines, and skin smoothness (fine texture), while 93.3% and 92.8% of respondents expressed visible improvement in brown spots and age spots, respectively. This demonstrates further a strong positive response to a measure of generalized improvement.

DISCUSSION

This is a pioneering study in that our methods dictate and examine a new, unique, barley-bioengineered EGF applied ex-vivo

to aged skin for cosmesis and reversal of clinical indicators of aging and photodamage. Epidermal growth factor itself is a 53 amino acid peptide generated by platelets and several subtypes of white blood cells (ie, macrophages and monocytes). For several decades, EGF has been known—largely within the research community—to aid in wound healing and tissue repair. Acting through both proliferative and migratory effects on most human cells, the EGF family of proteins binds with affinity differentiated specificity to 4 major receptors (3 of which are located in various strata of the skin) and has complex roles in the cascade inflammatory response, which are as of yet, not fully understood.^{1,8} However, our examined EGF protein binds nearly exclusively to the ErbB1 distinct receptor found in epidermal tissue.

EGF receptors are primarily found in fibroblasts, keratinocytes, and endothelial cells, the binding of which by EGF results in phosphorylation of tyrosine residues in the EGFR intracellular domain, subsequently triggering an elaborate cascade of intracellular signals and biochemical pathways ultimately leading to gene expression. The consummate effects of these events are cytoprotective, mitogenic, and anti-apoptotic upon proximate

TABLE 1. 90-Day Subject Self Assessment Questionnaire

n=15

"With respect to the condition of your skin before using the serum, cleanser and sunscreen, please rate the improvement you've experienced in terms of:"

Month 3

	Moderate, Great Improvement
Wrinkles	47%
Fine Lines	60%
Brown Spotting	60%
Red Spotting	53%
Age Spots	33%
Skin Smoothness (fine texture)	80%

Table 1: Subjects were questioned on perceived improvement in each listed category, given possible responses of *Worse, No Improvement, Little Improvement, Moderate Improvement, Great Improvement*. Responses within these two most significant categories are reflected as a percentage of total responders above. Fine lines are differentiated from wrinkles by definition of fine lines being those rhytids not visible by naked eye from a conversational distance of at least 18 inches from the face, while wrinkles are defined as those that are visible by naked eye from at least this distance.

FIGURE 7. Mean percentage improvement in fine lines and wrinkles in comparison to baseline. Month 1, n=25, Month 2, n=21, Month 3, n=15, $P < 0.0022$

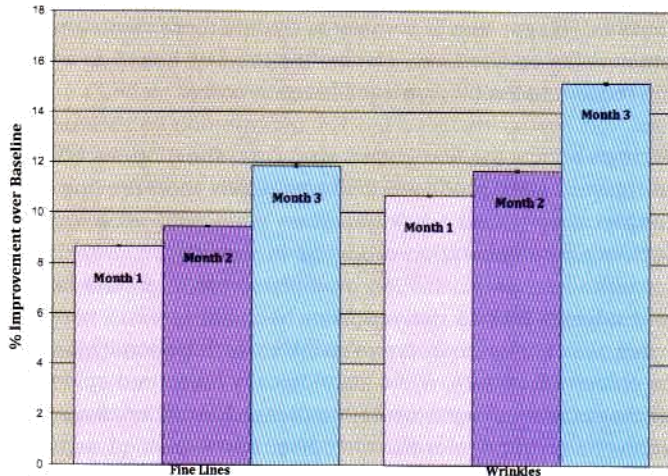
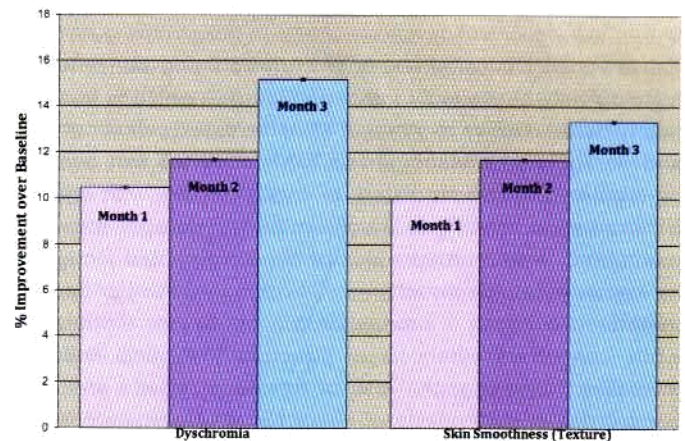


FIGURE 8. Mean percentage improvement in dyschromia and skin smoothness (texture) in comparison to baseline. Month 1, n=25, Month 2, n=21, Month 3, n=15, $P < 0.0022$



cells, initiating cellular proliferation, locomotion, survival, and repair of damaged cells, even following challenges of ultraviolet radiation or oxidative damage from free radicals or Reactive Oxygen Species (ROS). All of these enhanced functions have been proven necessary for healing, and to ensure the migration of proper immune cells to areas of injury, granulation tissue production, angiogenesis, and ultimately re-epithelialization.¹⁴

Epidermal growth factor influences several principal constituents of tissue organization including fibroblastic deposition of collagen and fibronectin, extracellular matrix proteins as well as plasma glycoproteins, and the rearrangement of the actin cytoskeleton, vital not only in wound healing, but also normal cellular differentiation and development. While necessary to wound healing

and cellular propagation, it has been proven that EGF does not contribute to tumorigenesis, a theoretically dangerous ancillary effect. A comprehensive safety analysis of all studies performed at the time of publishing on human subjects confirmed that although EGF exposure has an anticipated tumor-promoting effect on existing malignancies, it does not contribute to initiation, and no increased incidence of new malignancy is seen following various modalities of treatment in human subjects.^{14,15}

The earliest clinical research involving EGF took place in vivo in the late 1980's, and initially was shown to improve epidermal regeneration and healing times in damaged skin^{2,3} and the eye from such injuries as corneal abrasions.⁴ Epidermal growth factor infusion has since proven more conventionally

applicable in improving the healing times of ulcers in difficult patient cases where an ancillary condition may attenuate wound healing, such as in diabetics.^{5,7} In these studies, EGF injections were confirmed to accelerate healing of large ulcers and resulted in circumvention of amputation in high-risk subjects in over 65% of those subjects treated.⁷ A concurrently published case study reported a patient with a large radiation ulcer resistant to all conventional treatment for three years that successfully healed after only 4 months of topical EGF application.⁸ In another study of patients receiving radiation therapy to the head and neck, an oral EGF aerosol compound successfully reduced the incidence of severe oral mucositis significantly.⁹ Though its history and current applications with regard to generalized wound healing is obvious, our use of topical EGF serum in intact photodamaged and intrinsically aged skin is not immediately intuitive.

Cosmetically, UV exposure contributes in large part to a wide variety of more benign cutaneous changes. Superficially, these accumulated signs of photoaging commonly present either wrinkles or dyschromia, such as lentigines, freckles and nevi. Skin commonly becomes atrophied, thin, attenuated in elasticity, appears dry and rough, and is prone purpura and ecymoses from minor trauma.¹²

These varied clinical changes of intrinsic aging are reflected histologically by a visibly thinned epidermis which is less cellularly dense relative to younger skin, increased cellular atypia, and deregulated melanogenesis.¹⁷ Melanocytes can become up-regulated, down-regulated, or even inactive with chronic UV irradiation, leading to dyschromia (or heterogeneous pigmentation), with mottled zones of hyperpigmented lentigines as well as hypopigmented areas.¹² Within the reticular dermis, matured collagen 1 production via fibroblasts diminishes, while concurrent synthesis of structurally atypical collagen increases.¹⁸ Likewise, the loss of functional elastin and concurrent rise in hyperplasia of abnormal elastic tissue appears clinically as lesions of disorganized, thickened mesh, known as "solar elastoses."¹⁹ Concomitantly, atrophied dermal collagen architecture and ample solar elastotic materials provide little structural and cushioning support to the dermal blood vessels in intrinsically aged skin, predisposing the tissue to large ecymoses and purpura from minor trauma, often so minor as to be unrecalled by the patient. In the elderly, the ensuing extravasated red blood cells, hemosiderin pigment, and hemosiderin deposits are known as "solar" or "senile purpura," and are most commonly found on the dorsal forearms and hands, but also appear on the pretibia.²⁰

Chronic ultraviolet (UV) exposure from the sun can up-regulate the action of dermal matrix metalloproteinases (dMMP's), which serve to breakdown collagen 1, the primary structural component of dermal tissue, and disrupt elastic fibers, which

bridge the dermal-epidermal junction to the deep dermis. This action alters the configuration of the extracellular matrix and leads to increased wrinkling of sun-exposed skin, and to the thinning leading concurrently to this "senile purpura."^{13,16}

The stimulatory effects of EGF itself on fibroblasts lead to increased production of collagen 1 and therefore increase dermal thickness, all while stimulating epidermal resurfacing and exfoliation. In addition, neovascularization of partial thickness wounds in porcine models has also been observed.²¹ Given these findings in past research, it is not unexpected that topical application to photo and intrinsically aged skin appeared to decrease wrinkling in our subjects, likely through these improvements in both skin texture and relative thickness.

In addition to the external, clinical signs of photoaging, elderly skin has also been shown to present decreased numbers of functional EGF receptors embedded in fibroblast cell membrane for example, which attenuates response to the EGF ligand.¹⁰ Additionally, those functional EGFRs that remain suffer from increased protein phosphatase response, attenuating the EGF/EGFR complex signal transfer to the cell and concomitant EGF activity farther.¹¹ Introducing high levels of exogenous EGF to these EGFRs appears to partially overcome these shortcomings, presumably by effectively eliminating the EGF ligand as a limiting reagent to the binding equilibrium process.

Though ours is the first known study investigating the efficacy of topical barley produced EGF specifically in improving photoaged skin, similar work has been done with other growth factors and combination products. In a study on growth factor efficacy, a gel containing multiple common growth factors and other cytokines derived from neonatal foreskin keratinocytes, was shown to improve wrinkle depth periorally, as well as epidermal texture, while histologically measured epidermal thickness and collagen content increased. Additionally, a pilot study involving 6 months of topical application of a proprietary gel containing differential concentrations of 110 growth factors and other cytokines found improvement in fine lines and wrinkles compared to placebo, although the attributable ingredient(s) remains unclear due to the extensive formula.²²

CONCLUSION

In this study, regular topical application of the EGF serum regimen effectively reduced facial rhytids and improved several parameters of skin texture in subjects with moderate to severe photodamaged and aged skin to a statistically significant degree. Clinical improvement over baseline was observed to consistently increase over the length of the study for all measures and classes of data collected. The constitution of the utilized EGF serum as detailed in Figures 1 and 2, leads us to believe that exogenous dermal EGF introduction at this concentration or higher supplements existing physiological EGF for

cosmetic purposes, producing higher levels of normal collagen 1 in tissue, and overall dermal thickening and epidermal resurfacing and revitalization through several discussed processes. Epidermal growth factor itself has been shown in past research to improve healing times in wounded skin by promoting mobilization, proliferation, and activation of endothelial cells, fibroblasts, and keratinocytes, and some of these same actions, most significantly collagen production, likely account for the observed improvements in wrinkling and appearance.

In terms of clinical benefits, the application of this serum topically to newly re-epithelialized superficial wounds would expectedly decrease healing time and improve final cosmetic appearance through these same mechanisms, as well as theoretically require no retooling of serum formula or vehicle.

Future studies exploring applications of EGF could utilize a similarly formulated serum in a wound healing capacity, rather than for cosmesis, directed either at a superficial cut or laceration wounds, or the "senile purpura" commonly observed in clinics with patient populations of advanced age. Either design would presumably net significant improvement. Additionally, if a future study were conducted with an aim at cosmesis, it may benefit data collection and analysis to include a well considered clinical photography system that both minimizes patient movement (as our Canfield system did) as well as produces consistently lit and contrasted photographs for analysis, which was not optimally achieved within the constraints of our system. As well, the results of our study suggest that the use of a cutometer, for measures of extensibility and resiliency of skin during the course of the 3 months of treatment would have produced an observable decrease in extensibility and increase in resiliency, as consistent with our understandings of collagen function and the effects of skin aging, and reversal of the effects thereof.

The results of our study, as well as those of these prospective options, could be confirmed by histological sampling and analysis. It was elected not to include a biopsy component in this study due to tolerability and safety concerns of the subjects. However, the inclusion of such data would no doubt provide a wealth of information on collagen levels, improved dermal architecture and possibly even functional EGF levels in vivo if appropriate assays were performed, lending a bright future to this essential physiological protein.

ACKNOWLEDGEMENTS

Financial support of this study was provided by Moy-Fincher-Chipps Facial Plastics/Dermatology.

DISCLOSURES

Dr. Moy is an investigator for Moy-Fincher-Chipps Facial Plastics/Dermatology. Dr. Luu is an employee for Moy-Fincher-Chipps Facial Plastics/Dermatology. Mr. Schouest is an investigator-

consultant for Moy-Fincher-Chipps Facial Plastics/Dermatology. The authors alone are responsible for the content and writing of this paper.

REFERENCES

- Pastore S, Mascia F, Mariani V, Girolomoni G. The epidermal growth factor receptor system in skin repair and inflammation. *J Invest Dermatol.* 2008;128:1365-1374.
- Brown LG, Nanney BL, Griffen J et al. Enhancement of wound healing by topical treatment with epidermal growth factor. *N Engl J Med.* 1989;321:76-79
- Falanga V, Eaglstein WH, Bucalo B, Katz MH, Harris B, Carson P. Topical use of human recombinant epidermal growth factor (h-EGF) in venous ulcers. *J Dermatol Surg Oncol.* 1992;18:604-606.
- Pastor JC and Calonge M. Epidermal growth factor and corneal wound healing. *Cornea.* 1992;11:311-314.
- Tsang MW, Wonk WK, Hung CS et al. Human epidermal growth factor enhances healing of diabetic foot ulcers. *Diabetes Care.* 2003;26:1856-1861.
- Hong JP, Jung HD, Kim YW. Recombinant human epidermal growth factor (EGF) to enhance healing for diabetic foot ulcers. *Ann Plast Surg.* 2006;56:394-399.
- Fernandez-Montequin JI, Infante-Critia E, Valenzuela-Silva C et al. Intralesional injections of Citoprot-P (recombinant human epidermal growth factor) in advanced diabetic foot ulcers with risk of amputation. *Int Wound J.* 2007;4:333-343.
- Lee SW, Moon SY, Kim YH, Hong JP. The use of recombinant human epidermal growth factor to promote healing for chronic radiation ulcer. *Int Wound J.* 2007;4:216-220.
- Wu HG, Song SY, Kim YS et al. Therapeutic effect of recombinant human epidermal growth factor (RhEGF) on mucositis in patients undergoing radiotherapy, with or without chemotherapy, for head and neck cancer. A double-blind placebo-controlled prospective phase 2 multi-institutional clinical trial. *Cancer.* 2009;15:3699-3708.
- Shiraha H, Gupta K, Drabik K, Wells A. Aging fibroblasts present reduced epidermal growth factor (EGF) responsiveness due to preferential loss of EGF receptors. *J Biol Chem.* 2000;275:19343-19351.
- Tran KT, Rusu SD, Satish L, Wells A. Aging-related attenuation of EGF receptor signaling is mediated in part by increased protein phosphatase activity. *Exp Cell Res.* 2003;289:359-367.
- Benedetto AV. The environment and skin aging. *Clin Dermatol.* 1998;16:129-139.
- Lee JY, Kim YK, Seo JY, et al. Loss of elastic fibers causes skin wrinkles in sun-damaged human skin. *J Dermatol Sci.* 2008;50:99-107.
- Berlanga-Acosta J, Gavilondo-Cowley J, Lopez-Saura P et al. Epidermal growth factor in clinical practice – a review of its biological actions, clinical indications and safety implications. *Int Wound J.* 2009;6:331-346.
- Mimura Y, Ihn H, Jinnin M, Asona Y, Yamane K, Tamaki K. Epidermal growth factor induces fibronectin expression in human dermal fibroblasts via protein kinase C delta signaling pathway. *J Invest Dermatol.* 2004;122:1390-1398.

16. Leyden JJ. Clinical features of aging skin. *Br J Dermatol*. 1990;122(Suppl35):1-3.
17. Montagna W, Carlisle K. Structural changes in ageing skin. *Br J Dermatol*. 1990;122 (Suppl 35):61-70.
18. Wulf HC, Sandby-Moller J, Kobayasi T, Gniadecki R. Skin aging and natural photoprotection. *Micron*. 2004;35:185-191.
19. Uitto J, Fazio MJ, Olsen DR. Molecular mechanisms of cutaneous aging: age-associated connective tissue alterations in the dermis. *J Am Acad Dermatol*. 1989;1:614-622.
20. Carlson JA, Chen KR. Cutaneous pseudovasculitis. *Am J Dermatopathol*. 2007;29:44-55.
21. Nanney LB. Epidermal and dermal effects of epidermal growth factor during wound repair. *J Invest Dermatol*. 1990;94:624-629.
22. Mehta RC, Smith SR, Grove GL, et al. Reduction in facial photo-damage by a topical growth factor product. *J Drugs Dermatol*. 2008;7:864-871.
23. DNAEGF Renewal tm Renewal Foaming Cleanser, Ingredients: Water, Laurylglucosides, Hydroxypropylsulfonate, Polyquaternium-71, Guar Hydroxypropyl Trimonium Chloride, Polysorbate 20, Glycolic Acid, Cetrimonium Laureth-12 Succinate, PEG-7 Dimethicone, Arginine, Cetyl Hydroxyethicellulose, Phenoxxyethanol, Caprylyl Glycol, Ethylhexylglycerin, Hexylene Glycol, Sodium Hydroxide, Caprylic/Capric Triglyceride, Citrus Paradisi (Grapefruit) Oil, Citrus Aurantium Dulcis (Orange) Fruit Extract, Citrus Reticulata (Tangerine) Oil.
24. DNAEGF Renewal tm DNA Defense SPF 30+, Active Ingredients: Ethylhexyl Methoxycinnamate 7.5%, Oxybenzone 4%, Zinc Oxide 3%, Phenylbenzamidazole Sulfonic Acid 2%.
25. BIOEFFECT EGF Serum Active Ingredients: Glycerine, Aqua, Sodium hyaluronate, Tromethamine, Alcohol (less than 0.9%), Calcium chloride, Sodium chloride, Hordeum vulgare seed extract, EGF (Transgenic barley sh-oligopeptide-1).

ADDRESS FOR CORRESPONDENCE


Ronald L. Moy MD

Moy-Fincher-Chipps Facial Plastics and Dermatology
421 North Rodeo Drive
Terrace Level North
Beverly Hills, CA 90210

Phone:.....(310) 274-5372
Fax:.....(310) 274-5380
E-mail:.....rmoy@ucla.edu

New Supplement

Now Available



When and How to Use Biologics

JOURNAL OF DRUGS IN DERMATOLOGY
JDD
DRUGS • DEVICES • METHODS

Look for this supplement with your
May issue of *JDD* and *eJDD*.

This supplement to the *Journal of Drugs in Dermatology* is supported by an educational grant from Abbott Laboratories, Amgen and Janssen Biotech.

